

Post Cholecystectomy Biliary Leakage and its Management; Overview

¹Amnah Ahmed Alhuwayji, ²Amal Almass Ablushi

Abstract: Post Cholecystectomy Biliary Leakage (PCBL) is uncommon but can happen in 0.3-2.7% of patients. We aimed by this review to highlight the most etiological factors contributing in bile leakage after Cholecystectomy, but the main objective of this paper was to evaluate the treatment approaches for Post Cholecystectomy Biliary Leakage (PCBL), mostly surgical procedures in management of PCBL. We performed an electronic search through several databases; MIDLINE, and EMBASE to the date November 2016. A Medline search of the literature was done using keywords such as bile leakage and bile duct injury, surgical management of PCBL. When bile leak is identified after LC, it is very important to consider how the leak has actually emerged. Offered the variety of readily available treatments, ranging from a few days of observation to sophisticated biliary enteric coronary bypass, the etiology of the leak-age ought to be definitely figured out before any intervention happens, consequently reducing unnecessary exploration. When deciding upon the most suitable management of Bile Leakage After Laparoscopic Cholecystectomy exploration, numerous factors need to be evaluated. Many factors have to be assessed when deciding upon the most ideal management of bile leak, consisting of the surgeon's experience, availability of an endoscopist, cost-effectiveness, equipment requirements, and length of admission and follow-up.

Keywords: Post Cholecystectomy Biliary Leakage (PCBL), endoscopist.

1. INTRODUCTION

Post Cholecystectomy Biliary Leakage (PCBL) is uncommon but can happen in 0.3-2.7% of patients ^(1,2,3). It is defined as the persistent leakage of bile from the biliary tree. This can arise from an injury to the typical bile/hepatic duct but it is usually accepted that the vast bulk occur from the cystic duct stump or a sub-vesical duct of Luschka ⁽³⁾. A bile leakage may lead to a biliary fistula, a subhepatic/subphrenic collection and localized or generalized peritonitis. Plainly, this can be related to significant morbidity and even death, especially if it is not determined and dealt with at an early phase ⁽⁴⁾.

In the early 1990s when both laparoscopic cholecystectomy and minimally intrusive techniques were in their infancy, bile leakages were handled conservatively; if the patient did not enhance, a laparotomy was typically carried out. Management was anecdotal and based upon the experience of the surgeon. However, with the arrival of enhanced radiological percutaneous drainage, healing endoscopic retrograde cholangiography (ERC) ^(5,6,7) and increased self-confidence with laparoscopic techniques consisting of suturing ^(8,9), it ended up being clear that bile leaks could be handled in a minimally intrusive manner, possibly decreasing morbidity and mortality ⁽⁹⁾.

The introduction of laparoscopic cholecystectomy has dramatically changed the approach to gallstone disease over the last years. The laparoscopic technique has been associated with a greater occurrence of biliary complications, particularly in the early years of its adoption ^(10,11,12). Bile leakage after laparoscopic cholecystectomy is typically due to a small biliary issue, although it can sometimes declare a significant duct injury. Several series have reported bile leak rates of 1.2- 4-0 percent in laparoscopic cholecystectomy ^(13,14,15), which is greater than the incidence with open cholecystectomy ^(16,17,18).

We aimed by this review to highlight the most etiological factors contributing in bile leakage after Cholecystectomy, but the main objective of this paper was to evaluate the treatment approaches for Post Cholecystectomy Biliary Leakage (PCBL), mostly surgical procedures in management of PCBL.

2. METHODOLOGY

We performed an electronic search through several databases; MIDLINE, and EMBASE to the date November 2016. A Medline search of the literature was done using keywords such as bile leakage and bile duct injury, surgical management of PCBL. The published classifications, schemes, and management strategies for bile duct injury and bile leakage were also analyzed. we also searched the references of relevant identified articles for more evidence for managements approaches of Post Cholecystectomy Biliary Leakage.

3. RESULTS & DISCUSSION

Laparoscopic cholecystectomy (LC) was presented over 25 years ago and is ending up being the gold requirement of treatment for symptomatic cholelithiasis, even in patients with severe cholecystitis^(10,12,13). Nevertheless, LC is connected with a greater incidence of bile duct injury than open cholecystectomy, causing prolonged hospitalization, difficult reconstruction, and increased morbidity^(14,15). Although there has actually been much discussion about the classification and management of bile duct injury,^(14,15,17) the relationship between bile leakage and bile duct injury is still not totally comprehended. There is a need to establish a methodical technique to the management of bile leakage. The importance of the etiological classification of bile leak, which can be utilized to determine proper management techniques, has actually not been emphasized enough⁽¹⁸⁾.

The most typical sites of post-cholecystectomy bile leakage (PCBL) are the cystic duct stump and the duct of Luschka, which tend to be LG and frequently solve spontaneously^(19,20,21). The duct of Luschka describes an accessory bile duct that remains in close distance to the gallbladder body and can be injured during LC. Other types of PCBLs range from direct hepatic duct injury and leak to complete bile duct transection and are generally HG. Patients with HG leaks present within the very first post-operative week with relentless biliary discharge from a stomach drain left during surgery or varying degrees of abdominal pain and distension, constant with intraabdominal bile collections or bile peritonitis, jaundice, or perhaps sepsis. Ultrasound is the initial diagnostic test although in many LG cases medical diagnosis can be validated by a hepatobiliary imino-diacetic acid (HIDA) scan, also called cholecystography, or an endoscopic retrograde cholangiopancreatography (ERCP)⁽²²⁾.

We have actually identified an extremely important research study⁽²³⁾ that consisted of revealed that Bile leak throughout or after LC was seen in 16 patients, being 7 women and 9 males (**Table 1**), ranging in age from 33 to 71 years. Laparoscopic cholecystectomy was performed electively for symptomatic cholelithiasis in 3 of these patients (19%) and as an emergency situation procedure for severe cholecystitis in the other 13 (81%). The general incidence of the bile leakage in our series was 0.29% (12/4100; referred cases not consisted of), but when LC was performed for intense cholecystitis, the incidence was 1.37% (9/656), being obviously higher than that for elective surgery (0.09%, 3/3300; Fisher's exact test, $P < 0.001$). Bile leak was diagnosed as continuous drain-age of bile from the dissected location during LC in six patients; as consistent drain of bile-stained fluid from the drain tube in 9 patients; and as a sub-hepatic bile collection discovered 2 weeks post-LC in one patient who did not have drainage tubes positioned. The time that expired before the detection of bile leak in the previous 9 patients ranged from a couple of hours to 2 days after LC. The etiological classifications and particular management strategies were as follows⁽²³⁾.

Table1. Clinical features of 14 patients with bile leakage⁽²³⁾

| Age/sex | Procedure | Onset of bile leak | ERCP | Etiology and treatment |
|---------|-----------|--------------------|------|---|
| 48/M | Elective | Within 6 h | No | Laparotomy, suture ligation of cystic duct stump leak |
| 58/M | Acute | Within 6 h | No | Laparoscopic loop close of cystic duct stump leak |
| 71/M | Acute | Intraoperative | No | CBD transection, conversion, Roux-en-Y choledochojejunostomy |
| 57/F | Acute | Intraoperative | No | CBD transection, conversion, Roux-en-Y choledochojejunostomy |
| 39/M | Acute | Intraoperative | No | CBD puncture injury and conversion with T-tube choledochotomy |
| 65/M | Acute | Referred | Yes | CBD perforated injury and observation for 6 weeks |
| 37/M | Acute | Referred | Yes | CBD perforated injury and observation for 4 weeks |
| 44/F | Acute | 2 days | Yes | Retained CBD stone, cystic duct stump leak, laparotomy choledocholithotomy, T-tube choledochotomy |

| | | | | |
|------|----------|------------------|-----|--|
| 52/M | Acute | Intraoperative | No | CBD transection, conversion Roux-en-Y choledochojejunostomy |
| 52/F | Acute | 1 day | Yes | Cystic duct stump leak, observation 4 days and spontaneous stump closure |
| 68/F | Elective | Within 6 h | Yes | CBD transection, conversion, Roux-en-Y choledochojejunostomy |
| 42/M | Acute | Intraoperative | No | Liver bed leakage, Endo-clip clamp |
| 33/F | Acute | Intraoperative | No | CBD perforation, IOC and laparoscopic choledochotomy with T-tube |
| 52/F | Elective | 2 weeks (biloma) | No | Laparoscopic irrigation and drainage |
| 34/F | Acute | Referred | Yes | CBD transection, Roux-en-Y choledochojejunostomy |
| 63/M | Acute | Referred | Yes | CBD transection, Roux-en-Y choledochojejunostomy |

ERCP, endoscopic retrograde cholangiopancreatography; CBD, common bile duct; IOC, intraoperative cholangiography

Deziel et al. ⁽²⁴⁾ reviewed 77604 LCs, keeping in mind 223 cases (0.29%) of post-operative bile leakage. reported identifying the site of leak in 107 patients; as arising from the cystic duct in 57, the gallbladder fossa in 24, the CBD or hepatic duct in 18, an aberrant bile duct in 7, and the liver biopsy site in 1. Kept CBD stones were likewise found in 3 patients with cystic duct leakages ⁽²⁴⁾.

We have actually recognized a other big study ⁽²⁵⁾ that involving Twenty-four patients with a bile leakage following laparoscopic cholecystectomy were recorded consecutively between 1993 and 2003. revealing Prior to March 1998, bile leakages were handled on a caseby-case basis. Following this, a minimally intrusive protocol was set up in order to offer a clear stepwise approach for the management of bile leaks (Figure.1). If this is suspected on scientific grounds, the primary step is to develop and preserve adequate drainage. If a drain was left in situ at the preliminary treatment and continued to drain bile, this is left. If not, then an ultrasound scan (USS) is carried out and any collection determined drained percutaneously under USS assistance ⁽²⁵⁾.

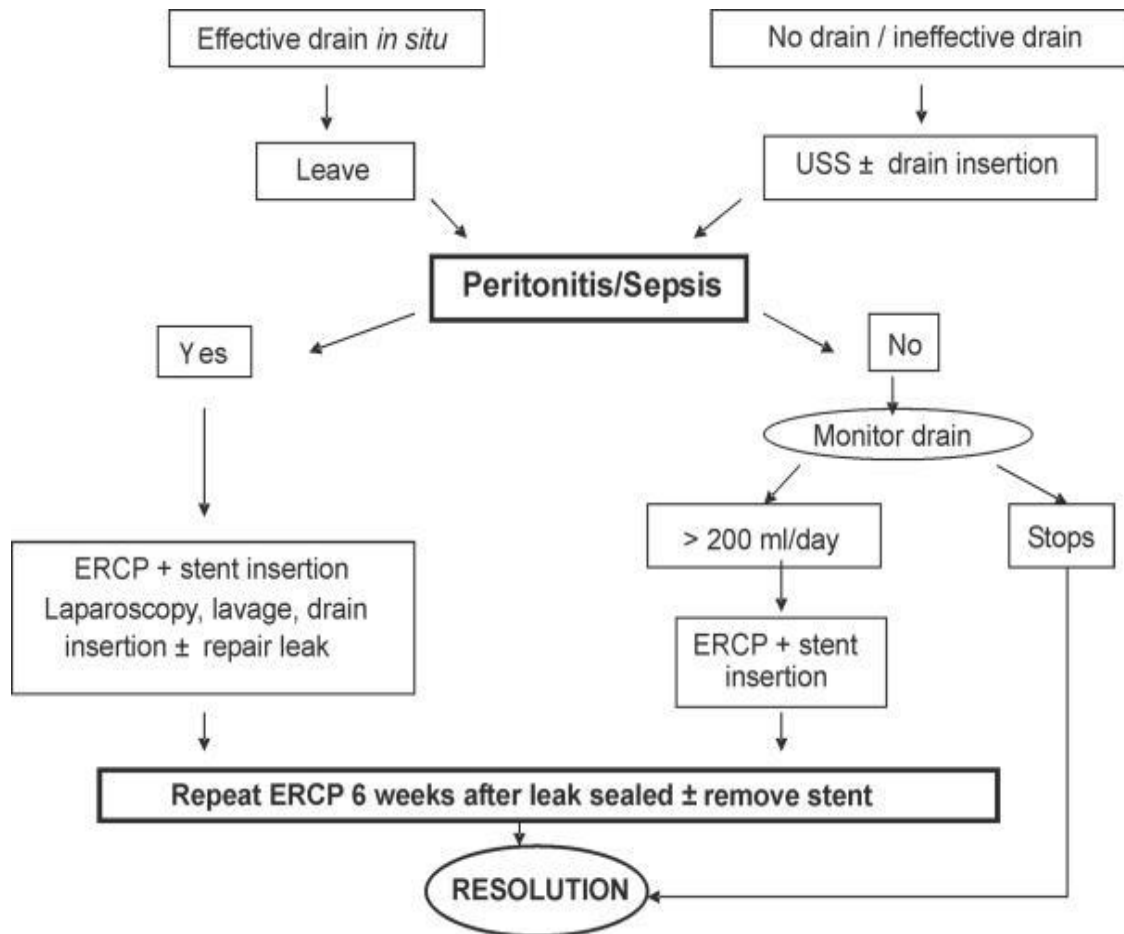


Figure 1. Protocol for the minimally invasive management of bile leaks post laparoscopic cholecystectomy (1998–2003) ⁽²⁵⁾.

The management procedures of PCBLs carried out are summed up ⁽²⁵⁾ in (Table 2) Prior to 1998, ERC was not routinely utilized in the management of patients with bile leaks. Although this settled with conservative management in 4 (40%) individuals, the staying 6 (60%) needed personnel intervention. The indications for surgery were biliary peritonitis following early drain removal in two, consistent drainage of bile (3, 5 and 8 days) in 3 and the development of a big subphrenic collection in association with a persistent bile leakage (20 days) in a septic patient on ITU. All six people underwent a laparotomy with on-table cholangiography consistently carried out. The site of the leakage was an inadequately secured cystic duct (n = 2), a hole simply proximal to clips/ligation of the cystic duct (n = 2) or a hole at the junction of the cystic duct and typical bile duct (CBD; n = 2). In each case, the site of the leakage was sutured and an extensive washout/drainage performed. CBD stones were just recognized in one individual who went on to have expedition of the CBD and stone removal with insertion of a T-tube. A postoperative T-tube cholangiogram was typical and this was eliminated 12 days after insertion ⁽²⁵⁾.

Table 2. Management of bile leaks before and after the introduction of a minimally invasive protocol ⁽²⁵⁾

| | No protocol 1993–1998 (n = 10) | Minimally invasive protocol 1998–2003 (n = 14) | P-value |
|---|-----------------------------------|---|---------|
| Percutaneous USS-guided aspiration/drainage | 3 (30) | 4 (29) | 1.00 |
| ERCP | 2 (20) | 11 (79) | 0.01 |
| Stone extracted | 0 | 4(29) | |
| Endoscopic sphincterotomy | 0 | 4(29) | |
| Stent insertion | 1 (10) | 10 (72) | |
| Laparoscopy | 0 | 5(36) | 0.05 |
| Laparotomy | 6 (60) | 0 (0) | < 0.01 |

Values expressed as raw data (%).

4. CONCLUSION

When bile leak is identified after LC, it is very important to consider how the leak has actually emerged. Offered the variety of readily available treatments, ranging from a few days of observation to sophisticated biliary enteric coronary bypass, the etiology of the leak-age ought to be definitely figured out before any intervention happens, consequently reducing unnecessary exploration. When deciding upon the most suitable management of Bile Leakage After Laparoscopic Cholecystectomy exploration, numerous factors need to be evaluated. Many factors have to be assessed when deciding upon the most ideal management of bile leak, consisting of the surgeon's experience, availability of an endoscopist, cost-effectiveness, equipment requirements, and length of admission and follow-up. With the exception of common bile duct; (CBD) transection, which demands an extended open treatment, as laparoscopic management is not feasible, all other types of bile leak may be treated more conservatively by observation, percutaneous trans-hepatic cholangiography, endoscopic treatments such as endoscopic naso-biliary tube drain (ENBD) or endoscopic papillotomy, or repeating laparoscopic procedures. Other evidence revealed a structured stepwise technique to the management of unusual problems such as bile leaks is helpful. In order to run such a procedure there should be the abilities and resources available to offer endoscopic retrograde cholangiography (ERC) and advanced laparoscopic surgical treatment.

REFERENCES

- [1] Vecchio R, MacFadyen BV, Latteri S. Laparoscopic cholecystectomy: an analysis of 114,005 cases of United States series. *Int Surg.* 1998;83:215–9.
- [2] Merrie AE, Booth MW, Shah A, Pettigrew RA, McCall JL. Bile duct imaging and injury. A regional audit of laparoscopic cholecystectomy. *Aust NZ J Surg.* 1997;67:706–11.
- [3] McMahan AJ, Fullarton G, Baxter JN, O'Dwyer PJ. Bile duct injury and bile leakage in laparoscopic cholecystectomy. *Br J Surg.* 1995;82:307–13.
- [4] Buanes T, Waage A, Mjaland O, Solheim K. Bile leak after cholecystectomy significance and treatment. Results from the National Norwegian Cholecystectomy Registry. *Int Surg.* 1996;81:276–9.

- [5] De Palma GD, Galloro G, Iuliano G, Puzziello A, Persico F, Masone S, et al. Leaks from laparoscopic cholecystectomy. *Hepatogastroenterology*. 2002;49:924–5.
- [6] Mergener K, Strobel JC, Suhocki P, Jowell PS, Enns RA, Branch MS, et al. The role of ERCP in diagnosis and management of accessory bile duct leaks after cholecystectomy. *Gastrointest Endosc*. 1999;50:527–31.
- [7] Ryan ME, Geehen JE, Lehman GA, Aliperti G, Freeman ML, Silverman WB, et al. Endoscopic intervention for biliary leaks after laparoscopic cholecystectomy: a multicentre review. *Gastrointest Endosc*. 1998;47:261–6.
- [8] Azagra JS, DeSimone P, Goergen M. Is there a place for laparoscopy in the management of post-cholecystectomy biliary injuries? *World J Surg*. 2001;25:1331–4.
- [9] Wills VL, Jorgensen JO, Hunt DR. Role of relaparoscopy in the management of minor bile leakage after laparoscopic cholecystectomy. *Br J Surg*. 2000;87:176–80.
- [10] Cushieri A, Dubois F, Mouiel J, et al. The European experience with laparoscopic cholecystectomy. *Am J Surg*. 1991;161:385–7. [PubMed]
- [11] Bailey RW, Zucker KA, Flowers JL, et al. Laparoscopic cholecystectomy experience with 375 patients. *Ann Surg*. 1991;234:531–41. [PMC free article] [PubMed]
- [12] Woods MS, Traverso LW, Kozarek RA, et al. Characteristics of biliary tract complications during laparoscopic cholecystectomy: a multi-institutional study. *Am J Surg*. 1994;167:27–33. [PubMed]
- [13] Brooks DC, Becker JM, Connors PJ, Carr-Locke DL. Management of bile leaks following laparoscopic cholecystectomy. *Surg Endosc*. 1993;7:292–5. [PubMed]
- [14] Kozarek RA, Traverso LW. Endoscopic stent placement for cystic duct leak following laparoscopic cholecystectomy. *Gastrointest Endosc*. 1991;37:71–3.
- [15] Ponsky JL. Complications of laparoscopic cholecystectomy. *Am J Surg*. 1991;161:393–5.
- [16] Morgenstein L, Wong L., Berci G. Twelve hundred open cholecystectomies before the laparoscopic era: a standard for comparison. *Arch Surg*. 1992;127:400–3. [PubMed]
- [17] Palestrant AM, Vine HS, Sacks BA, Weinstein M, Ellison H. Nonoperative drainage of fluid collections following operations on the biliary tract. *Surg Gynaecol Obstet*. 1983;156:305–9.
- [18] The Southern Surgeons Club. A prospect analysis of 1518 laparoscopic cholecystectomies. *N Engl J Med* 1991;324:1073–8.
- [19] Barkun AN, Rezieg M, Mehta SN, et al. Postcholecystectomy biliary leaks in the laparoscopic era: risk factors, presentation, and management. McGill Gallstone Treatment Group. *Gastrointest Endosc* 1997;45:277-282.
- [20] Kitami M, Murakami G, Suzuki D, et al. Heterogeneity of subvesical ducts or the ducts of Luschka: a study using drip-infusion cholangiography-computed tomography in patients and cadaver specimens. *World J Surg* 2005;29:217-223.
- [21] Ko K, Kamiya J, Nagino M, et al. A study of the subvesical bile duct (duct of Luschka) in resected liver specimens. *World J Surg* 2006;30:1316-1320.
- [22] Bergman JJ, van den Brink GR, Rauws EA, et al. Treatment of bile duct lesions after laparoscopic cholecystectomy. *Gut* 1996;38:141-147.
- [23] Lien HH1, Huang CS, Shi MY, Chen DF, Wang NY, Tai FC, Chen SH, Lai CY. Management of bile leakage after laparoscopic cholecystectomy based on etiological classification. *Surg Today*. 2004;34(4):326-30.
- [24] Deziel DJ, Millikan KW, Economou SG, Doolas A, Ko ST, Airan MC. Complications of laparoscopic cholecystectomy: a national survey of 4292 hospitals and an analysis of 77604 cases. *Am J Surg* 1993;165:9–14.
- [25] F Ahmad, RN Saunders, GM Lloyd, DM Lloyd, and GSM Robertson. An Algorithm for the Management of Bile Leak Following Laparoscopic Cholecystectomy. *Ann R Coll Surg Engl*. 2007 Jan; 89(1): 51–56.